

# Antiretroviral-Free HIV-1 Remission and Viral Rebound After Allogeneic Stem Cell Transplantation

## Report of 2 Cases

Timothy J. Henrich, MD; Emily Hanhauser, BS; Francisco M. Marty, MD; Michael N. Sirignano, BS; Sheila Keating, PhD; Tzong-Hae Lee, MD, PhD; Yvonne P. Robles, BA; Benjamin T. Davis, MD; Jonathan Z. Li, MD; Andrea Heisey, BS; Alison L. Hill, PhD; Michael P. Busch, MD, PhD; Philippe Armand, MD, PhD; Robert J. Soiffer, MD; Marcus Altfield, MD, PhD; and Daniel R. Kuritzkes, MD

**Background:** It is unknown whether the reduction in HIV-1 reservoirs seen after allogeneic hematopoietic stem cell transplantation (HSCT) with susceptible donor cells is sufficient to achieve sustained HIV-1 remission.

**Objective:** To characterize HIV-1 reservoirs in blood and tissues and perform analytic antiretroviral treatment interruptions to determine the potential for allogeneic HSCT to lead to sustained, antiretroviral-free HIV-1 remission.

**Design:** Case report with characterization of HIV-1 reservoirs and immunity before and after antiretroviral interruption.

**Setting:** Tertiary care center.

**Patients:** Two men with HIV with undetectable HIV-1 after allogeneic HSCT for hematologic tumors.

**Measurements:** Quantification of HIV-1 in various tissues after HSCT and the duration of antiretroviral-free HIV-1 remission after treatment interruption.

**Results:** No HIV-1 was detected from peripheral blood or rectal mucosa before analytic treatment interruption. Plasma HIV-1 RNA and cell-associated HIV-1 DNA remained undetectable until 12 and

32 weeks after antiretroviral cessation. Both patients experienced rebound viremia within 2 weeks of the most recent negative viral load measurement and developed symptoms consistent with the acute retroviral syndrome. One patient developed new efavirenz resistance after reinitiation of antiretroviral therapy. Reinitiation of active therapy led to viral decay and resolution of symptoms in both patients.

**Limitation:** The study involved only 2 patients.

**Conclusion:** Allogeneic HSCT may lead to loss of detectable HIV-1 from blood and gut tissue and variable periods of antiretroviral-free HIV-1 remission, but viral rebound can occur despite a minimum 3-log<sub>10</sub> reduction in reservoir size. Long-lived tissue reservoirs may have contributed to viral persistence. The definition of the nature and half-life of such reservoirs is essential to achieve durable antiretroviral-free HIV-1 remission.

**Primary Funding Source:** Foundation for AIDS Research and National Institute of Allergy and Infectious Diseases.

*Ann Intern Med.* 2014;161:319-327. doi:10.7326/M14-1027 [www.annals.org](http://www.annals.org)

For author affiliations, see end of text.

This article was published online first at [www.annals.org](http://www.annals.org) on 22 July 2014.

A major challenge in eradicating HIV-1 is the persistence of latently infected cells, which are established by integration of the viral genome into host cell chromosomes (1, 2). Combination antiretroviral therapy (ART) reduces plasma HIV-1 RNA levels to below the limit of detection of clinical assays. However, low-level plasma viremia or cell-associated HIV-1 DNA are detected in most patients receiving ART, even after intensification of the antiretroviral regimen (3–5). Furthermore, the virus typically rebounds within 1 to 8 weeks after treatment interruption in patients receiving long-term suppressive ART (6–11). As a result, ART-free HIV-1 remission (that is, “functional” cure) remains elusive.

Sustained HIV-1 remission for more than 7 years has been demonstrated in a patient with chronic infection (the “Berlin patient”) who had myeloablative, allogeneic hematopoietic stem cell transplantation (HSCT) for acute myelogenous leukemia using cells from a donor with a homozygous 32–base pair deletion in the gene encoding CCR5, a coreceptor for HIV-1 (12–14). The extent of reduction in the pool of latently infected cells in the blood and other tissues required to achieve sustained HIV-1 remission is unknown.

We previously reported reduction in peripheral blood HIV-1 reservoirs after allogeneic HSCT with reduced-intensity conditioning in 2 male patients with chronic HIV-1 infections (15). Both patients had heterozygous 32–base pair deletions in the gene encoding CCR5 but received HIV-1–susceptible, wild-type donor cells. Neither HIV-1 DNA nor HIV-1 RNA was detectable in circulating CD4<sup>+</sup> cells or plasma, respectively, after donor cells replaced host cells under the cover of suppressive ART. Anti-HIV antibody levels and avidity decreased after HSCT, a phenomenon also seen in the Berlin patient (14, 15). However, extensive sampling of tissues and large numbers of peripheral blood mononuclear cells (PBMCs) for the presence of HIV-1 is necessary to understand the full effect of allogeneic HSCT on HIV-1 persistence. Analytic treatment interruption (ATI) is necessary to establish that viral remission has been achieved. Therefore, we conducted an in-depth analysis of HIV-1 persistence in various tissues from our patients and performed closely monitored ATIs.

See also:

Editorial comment. . . . . 368

**Context**

Because HIV can be detected in patients even when they are receiving long-term suppressive antiretroviral therapy (ART) and can rebound within weeks of stopping, HIV therapy is currently recommended as a lifelong treatment.

**Contribution**

Two patients with HIV who had allogeneic hematopoietic stem cell transplants with HIV-1-susceptible wild-type donor cells achieved sustained HIV remission many weeks after stopping ART. However, both patients have now developed detectable virus in blood, as well as the acute retroviral syndrome, and ART has been reinitiated.

**Implication**

HIV can rebound even after a significant reduction in HIV reservoir size. An HIV cure remains elusive.

—The Editors

**METHODS****Tissue Collection, Apheresis, and Sample Processing**

The Dana-Farber/Harvard Cancer Center Office for Human Research Studies (Boston, Massachusetts) approved this study. Both patients had previously provided consent for blood and excess tissue sampling and were aware of these results before participating in this study. After full human research committee review, we initiated a second informed consent process that offered patients the option to have PMBC collection by apheresis, cerebrospinal fluid (CSF) collection, gut-associated lymphoid tissue sampling by anoscopy, and carefully monitored ATIs after reservoir characterization with permission from their clinical care providers. Peripheral blood mononuclear cells were collected by leukapheresis and were purified by Ficoll-Hypaque density gradient centrifugation. In addition, up to 120 mL of whole blood were obtained from patients at 3-month intervals for plasma collection and isolation of PBMCs. Cells were used when fresh or cryopreserved for later testing. Rectal biopsy samples were flash frozen or cells were disassociated and cryopreserved after Percoll centrifugation, as previously described (16, 17).

**Assays to Quantify and Characterize HIV-1 Reservoirs**

We extracted DNA from PBMCs and gut tissue using the QIAamp DNA Blood Mini Kit or the AllPrep DNA/RNA Mini Kit (Qiagen). HIV-1 DNA was quantified using a sensitive real-time polymerase chain reaction (PCR) assay, as previously described (18, 19). Polymerase chain reaction assays were performed in as many as 42 assay wells. A single-copy assay capable of detecting plasma HIV-1 RNA at a lower limit of detection of 0.4 copies/mL was performed (20). Viral outgrowth assays were performed in 30 to 32 replicate assays using aliquots of 5 million purified CD4<sup>+</sup> T cells, for a total of 150 million or more CD4<sup>+</sup> cells, in order to determine the presence of

replication-competent HIV-1 before ATI (21–23). The Cobas TaqMan HIV-1 Test, version 2.0 (Roche Molecular Systems), was used to quantify HIV-1 RNA in CSF. Homology among proviral DNA before HSCT and primers and probes used in the quantitative PCR assays was verified for each patient, and positive controls were incorporated in each assay, as previously described (15). Cells from a patient who had autologous HSCT with detectable HIV-1 DNA were used as positive controls in the viral outgrowth experiments. A single-genome analysis of near-full-length HIV-1 envelope sequences (approximately 2.5 kb) was done on cell-associated DNA before loss of detectable HIV-1 DNA and on plasma RNA after viral rebound, as previously described (24). Maximum likelihood phylogenetic trees of single-genome sequences were constructed using PhyML.

**HIV-1-Specific Immune Responses and Host Microchimerism**

Longitudinal quantification of HIV-specific antibody avidity by limiting-antigen enzyme immunoassay and antibody levels using the less sensitive (1:400 diluted plasma) Vitros Anti-HIV-1+2 assay (Ortho Clinical Diagnostics) were performed, as previously described (25). Peripheral blood mononuclear cells were used to perform interferon- $\gamma$  enzyme-linked immunospot assays incorporating overlapping peptides that represented the gag and nef consensus protein sequence of clade B HIV. Selected HIV-1 peptides (spanning gp160, vif, nef, p24, p17, reverse transcriptase, and protease) described to be presented by the patients' HLA class I molecules were used to determine HIV-1-specific cellular immune responses (26). Highly sensitive allele-specific PCR assays targeting HLA and insertion-deletion polymorphisms unique to the patient or donor were used to determine levels of host microchimerism in blood (that is, the proportion of residual host PBMCs after HSCT) (27, 28). The microchimerism assay is highly specific and sensitive to a single copy of target DNA, allowing detection of host cells present as a very low proportion of the PBMC population depending on the number of cells surveyed (27).

**ATI**

Carefully monitored ATIs were performed incorporating weekly viral load (VL) testing by the Cobas TaqMan HIV-1 Test, version 2.0 (limit of quantification of RNA levels of 20 copies/mL and limit of detection as low as 5 to 10 copies/mL), during the first 10 weeks after ART discontinuation and every 1 to 2 weeks thereafter. Qualitative testing of HIV-1 DNA from whole blood (Quest Diagnostics) was done approximately every 2 weeks. According to our institutional research guidelines, we were only able to provide patients with live-time results from approved clinical assays during this study. We planned to restart a patient's previous ART at the first sign of plasma viral rebound (any HIV-1 RNA level >1000 copies/mL or any confirmed VL >200 copies/mL). Large-volume blood col-

**Table 1. Studies to Assess HIV-1 Reservoirs After Allogeneic HSCT and Before ART Interruption**

Sample Type	Level	Total Cells Tested, <i>n</i>	Positive Wells/ Total Wells, <i>n/N</i>
<b>Patient A (4.3 y after HSCT)</b>			
Total HIV-1 PBMC DNA	<0.12 copies/10 <sup>6</sup> cells	26 × 10 <sup>6</sup> PBMCs	0/42
Infectious virus by viral outgrowth assay	<0.007 IUPM cells*	150 × 10 <sup>6</sup> CD4 <sup>+</sup> T cells	0/30
<b>Patient B (2.6 y after HSCT)</b>			
Total HIV-1 PBMC DNA	<0.13 copies/10 <sup>6</sup> cells	24 × 10 <sup>6</sup> PBMCs	0/42
Infectious virus by viral outgrowth assay	<0.006 IUPM cells*	160 × 10 <sup>6</sup> CD4 <sup>+</sup> T cells	0/32
Rectal tissue	<2.4 copies/10 <sup>6</sup> cells	1.23 × 10 <sup>6</sup> nucleated cell†	0/22

ART = antiretroviral therapy; HSCT = hematopoietic stem cell transplantation; IUPM = infectious units per million; PBMC = peripheral blood mononuclear cell.

\* No replication-competent HIV-1 was recovered.

† 25% of CD4<sup>+</sup> T cells were tested using flow cytometry after tissue disaggregation.

lections for detailed immunologic and virologic reservoir characterization as described previously were planned every 12 weeks before and after cessation of ART. HIV-1 genotyping of plasma virus was done either by Quest Diagnostics or by our laboratory, as previously described (29).

### Role of the Funding Source

This study was supported by the American Foundation for AIDS Research and the National Institute of Allergy and Infectious Diseases. The funding source had no role in the design or analysis of the study, the preparation of the manuscript, or the decision to submit the manuscript for publication.

## RESULTS

### Virologic and Immunologic Characteristics Before ART Discontinuation

Patient A was perinatally infected, and he had allogeneic HSCT with reduced-intensity conditioning for recurrent Hodgkin lymphoma. Patient B was a man with sexually acquired HIV who had allogeneic HSCT with reduced-intensity conditioning for the myelodysplastic syndrome after treatment of non-Hodgkin lymphoma and subsequent Hodgkin lymphoma. Both patients received sirolimus, tacrolimus, and short-course methotrexate to prevent acute graft-versus-host disease after HSCT. Patient A developed chronic graft-versus-host disease of the skin, eye, and liver and was treated with prednisone 9 months after HSCT with initial response. Patient B developed graft-versus-host disease of the skin, liver, and oropharynx 220 days after HSCT, requiring intermittent oral prednisone.

Given the lack of detectable HIV-1 from peripheral blood, as previously reported (15), patients A and B were approached again and provided written informed consent to have in-depth sampling. Leukapheresis was done 4.3 years after HSCT for patient A and 2.6 years after HSCT for patient B. Table 1 summarizes virologic tests done before ATI. No HIV-1 DNA was detected from PBMCs by sensitive quantitative PCR assay, and no replication-competent HIV-1 was recovered from coculture assays in-

volving 150 million or more purified CD4<sup>+</sup> T cells from either patient. Patient B consented to have rectal biopsy, in which no HIV-1 DNA could be detected. Microchimerism testing revealed that less than 0.0010% of peripheral blood cells were of host origin 1416 and 736 days after transplantation for patients A and B, respectively.

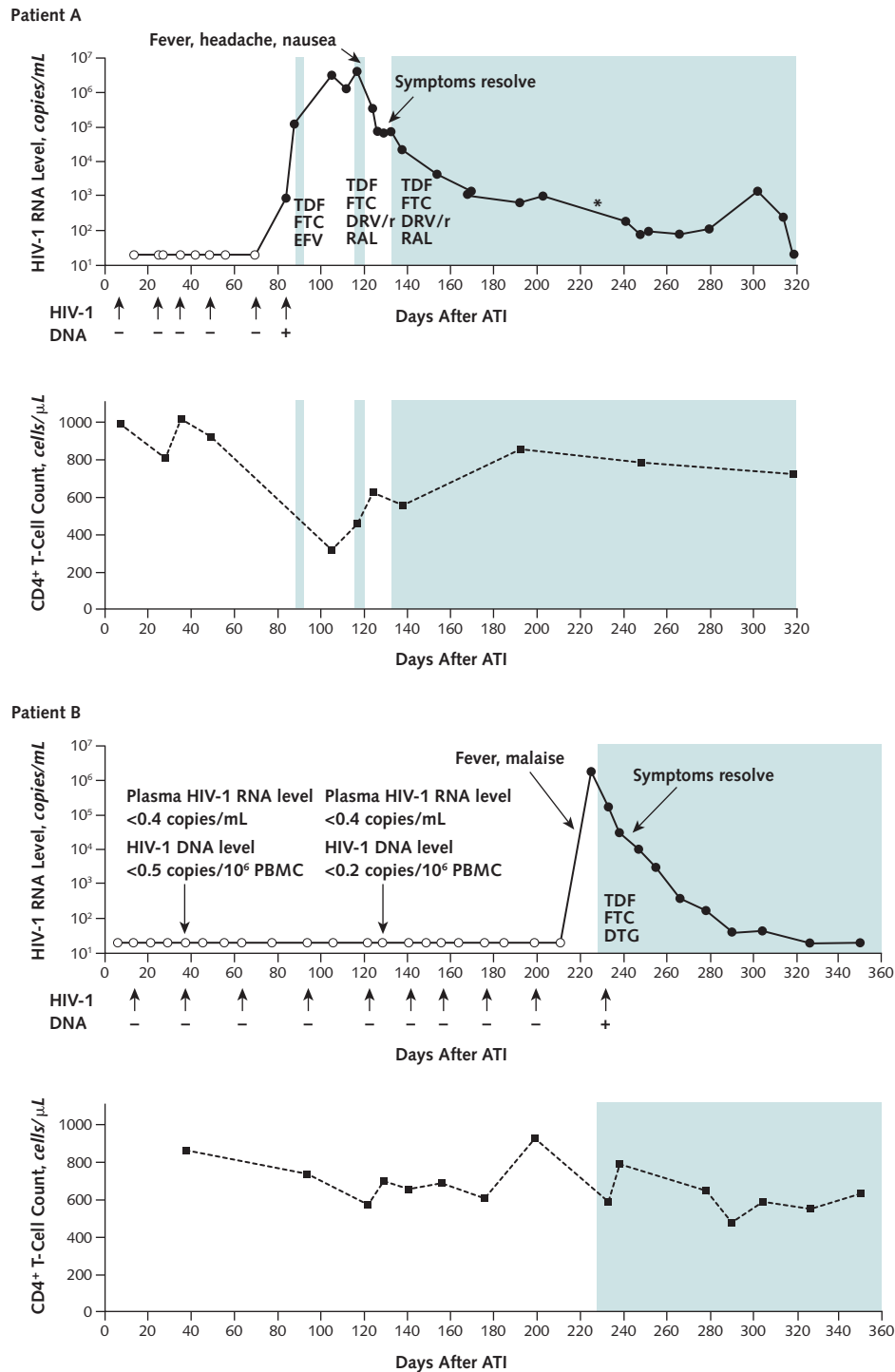
No significant HIV-1-specific cellular immune responses were detected in PBMCs of either patient before or after HSCT and before ATI by enzyme-linked immunospot assay (<30 spots per 10<sup>6</sup> PBMCs). However, PBMCs from patient B, who had a history of cytomegalovirus infection, demonstrated activation on stimulation with pooled cytomegalovirus, Epstein-Barr virus, and influenza peptides 652 days after HSCT.

### Treatment Interruption and Viral Rebound

Given the lack of detectable HIV-1 despite extensive sampling, we performed ATI with close monitoring for virologic rebound. The study team and all clinical providers, including oncologists and infectious disease specialists, were aware of results from additional reservoir testing and made joint decisions to offer ATI to each patient. After thorough discussion of the uncertain significance of virologic assays and potential risks of ATI, including viral rebound, the acute retroviral syndrome, or exacerbation of graft-versus-host disease, both patients consented to interrupt ART. Figure 1 shows the clinical, virologic, and immunologic course after ART discontinuation. Table 2 shows results from frequent blood sampling for quantification of cell and plasma virus. During ATI, patients A and B had no detectable plasma RNA or cell-associated HIV-1 DNA until 12 and 32 weeks after ART cessation, respectively. Patient A continued treatment with tacrolimus for persistent graft-versus-host disease during ATI; patient B did not require treatment during this period.

In patient A, viremia was first detected in plasma by clinical VL assay 84 days after ATI (RNA level, 904 copies/mL), 14 days after a negative clinical VL test result. He was initially asymptomatic and was asked to immediately restart his previous ART regimen (tenofovir plus emtricit-

Figure 1. Detection of HIV-1 and clinical course after ATI.



Results from clinical monitoring of quantitative HIV-1 plasma RNA and qualitative whole-blood HIV-1 DNA testing for both patients. Open circles or minus signs denote samples in which no HIV-1 was detected. Shaded areas represent the use of combination ART. In patient A, HIV-1 was first detected 12 wk after ATI (+). Clinical symptoms of the acute retroviral syndrome followed a rapid increase in plasma viral load and resolved at the time of active ART reinitiation. A plasma RNA level of 20 202 copies/mL was recorded 226 d after ATI (\*), but this may have been due to sample switching in the clinical laboratory. CD4<sup>+</sup> T-cell counts transiently declined during the time of peak viremia. In patient B, HIV-1 was first detected 32 wk after ATI (+). In addition, no HIV-1 DNA or plasma RNA was detected by sensitive research assays 38 and 129 d after ART discontinuation. Clinical symptoms of the acute retroviral syndrome occurred approximately 7 d after the last negative viral load test result. Symptoms resolved with prompt initiation of ART and subsequent viral suppression. ART = antiretroviral therapy; ATI = analytic treatment interruption; DRV/r = ritonavir-boosted darunavir; DTG = dolutegravir; EFV = efavirenz; FTC = emtricitabine; PBMC = peripheral blood mononuclear cell; RAL = raltegravir; TDF = tenofovir disoproxil fumarate.



abine plus efavirenz), according to protocol, after follow-up testing 4 days later revealed a VL increase to 127 843 copies/mL and HIV-1 in his CSF (<20 copies/mL). His VL subsequently peaked at an RNA level of 4.2 million copies/mL at 117 days after ATI, which may have been due in part to suboptimal medication adherence. HIV resistance testing done 112 days after ATI revealed a new efavirenz-resistant mutation (K103N), as well as resistance to several protease inhibitors (consistent with his history of treatment regimens), with the exception of tipranavir and darunavir. Given the emergence of drug resistance and rapidly increasing plasma viremia of uncertain cause, the patient was prescribed tenofovir plus emtricitabine plus raltegravir plus ritonavir-boosted darunavir and reduced-dose tacrolimus 117 days after ATI. However, he developed nausea, vomiting, headaches, and fever thought to be secondary to the acute retroviral syndrome, and he was only able to take several doses. He was evaluated at an outside hospital emergency department 120 days after ATI, where he had CSF sampling and was found to have low-grade lymphocytic pleocytosis (11 leukocytes per high-powered field) consistent with HIV-associated meningitis, but HIV-1 RNA was not measured in his CSF at this time. His symptoms may have been exacerbated by ART and tacrolimus coadministration.

The patient was discharged but continued to have difficulty taking medication, given central nervous system symptoms and vomiting thought to be due to the acute retroviral syndrome and potential medication side effects. He was admitted to our hospital for work-up and ART was reinitiated. The tacrolimus trough level peaked at 104 ng/mL (desired range <10 ng/mL) shortly after hospital admission when receiving concomitant ritonavir. He also had an increased serum creatinine level of 150.3  $\mu$ mol/L (1.7 mg/dL), but renal function and tacrolimus levels returned to normal within 4 days after both ART and tacrolimus were withheld. His symptoms resolved with decreasing viral RNA levels before ART reinitiation; ART was resumed along with very low doses of tacrolimus (0.5 mg every 3 weeks) 133 days after ATI with continued viral decay.

Patient B had frequent negative HIV-1 clinical laboratory test results during ATI and undetectable PBMC-associated HIV-1 DNA and plasma HIV-1 RNA by quantitative PCR assays (limits of detection, DNA level of 0.2 and 0.5 copies/ $10^6$  PBMCs and RNA level of 0.4 copies/mL) 5 and 18 weeks after ATI (Table 2). However, he developed fever, malaise, and fatigue 219 days after ATI, 8 days after a negative clinical VL test result. The patient presented to an outpatient urgent care center with worsening symptoms 225 days after ATI and was found to have a plasma HIV-1 RNA level of 1.9 million copies/mL.

He promptly resumed ART 228 days after ATI with tenofovir plus emtricitabine and dolutegravir, and symptoms resolved with subsequent decay of plasma viremia (Figure 1). No resistance-associated mutations were de-

**Table 2. HIV-1 Plasma RNA and Cell-Associated DNA Levels During ATI**

Sample Day After ATI	Plasma RNA Level, copies/mL	Whole-Blood or PBMC DNA Level
<b>Patient A</b>		
7, 25, 35, 49, 70	–	DNA not detected on all days (blood)*
14, 25, 28, 35, 42, 49, 56, 70	<20†	–
84	904	DNA detected (blood)
88‡	127 843	13 copies/ $10^6$ PBMCs
105	3 225 526	–
112	1 255 960	–
117	4 173 922	676 copies/ $10^6$ PBMCs
124	345 634	–
126	77 504	–
130	66 977	–
133	73 369	–
138	23 222	–
154	4344	–
170	1388	–
168	1114	–
192	646	105 copies/ $10^6$ PBMCs
203	1028	–
226	20 202§	–
241	183	–
248	75	–
252	93	–
266	81	–
280	110	–
302	1420	–
314	255	–
319	21	–
<b>Patient B</b>		
14, 30, 64, 94, 122, 141, 156, 176, 199	–	DNA not detected on all days (blood)*
38	<0.4	<0.5 copies/ $10^6$ PBMCs†
129	<0.4	<0.2 copies/ $10^6$ PBMCs†
7, 14, 22, 30, 38, 46, 56, 64, 78, 94, 106, 122, 129, 141, 149, 156, 164, 176, 185, 199, 211	<20†	–
225	1 900 000	–
233	174 577	–
238¶	32 185	1100 copies/ $10^6$ PBMCs
247	10 269	–
255	3160	–
266	385	–
278	171	318 copies/ $10^6$ PBMCs
290	42	–
304	44	–
326	<20 (detected)	–
350	<20 (detected)	–

ATI = analytic treatment interruption; PBMC = peripheral blood mononuclear cell.

\* A clinical laboratory validated that the detection threshold was an HIV-1 DNA level of 250 copies/mL of whole blood, but the assay may detect fewer DNA copies.

† No HIV-1 was detected.

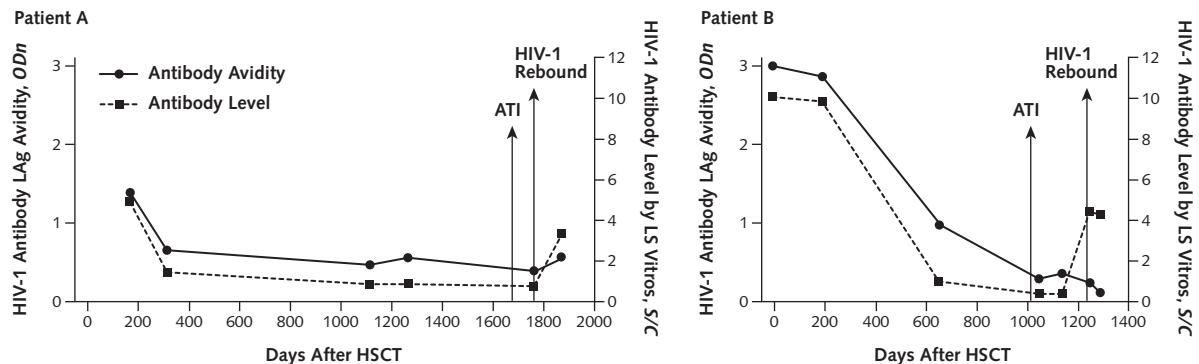
‡ RNA was detected in cerebrospinal fluid, but it was <20 copies/mL.

§ The positive value may have been due to a sample mix-up at the laboratory. We could not verify that the sample was from day 226 and not an earlier time.

|| No RNA was detected by single-copy assay.

¶ Cerebrospinal fluid viral load was 269 copies/mL.

Figure 2. Anti-HIV-1 antibody avidity by LAg assay before and after ATI.



HIV-1 antibody levels and avidity decreased in both patients during virologic suppression after allogeneic HSCT (including time points before ATI, as previously reported [15]). Antibody levels measured by the LS Vitros Anti-HIV-1+2 assay (Ortho Clinical Diagnostics) increased in both patients shortly after viral rebound. Antibody avidity increased slightly after viral rebound in patient A, in whom virologic control was not immediately reestablished, but continued to decrease in patient B, who promptly resumed ART after the first detectable viral load measurement. ART = antiretroviral therapy; ATI = analytic treatment interruption; HSCT = hematopoietic stem cell transplantation; LAg = limiting antigen; LS = less sensitive; ODn = normalized optical density measured by limiting-antigen avidity enzyme immunoassay; S/C = signal-cutoff ratio of the Vitros assay.

ected in plasma virus 233 days after ATI despite a history of nonnucleoside reverse transcriptase inhibitor resistance before HSCT. In addition, he had HIV-1 RNA levels of 269 copies/mL in his CSF 238 days after ATI.

Single-genome, near-full-length HIV-1 envelope sequences from rebound viremia in both patient A (44 sequences) and patient B (50 sequences) were related to peri-HSCT HIV-1 DNA sequences in phylogenetic analyses. Viral sequences from each patient after rebound were monophyletic with a high degree of intrasample sequence homology (Appendix Figure, available at [www.annals.org](http://www.annals.org)).

#### HIV-1-Specific Immunity After Treatment Discontinuation

No activation of PBMCs in response to HLA-matched peptides or pooled overlapping HIV-1 peptides in enzyme-linked immunospot assays were detected in samples from patients A and B before ATI, or from samples from patient B obtained before viral rebound at 38 and 129 days after ATI (PBMCs were not collected for time points after ATI but before rebound in patient A). Activation was seen in response to an HLA-A02–restricted nef peptide in PBMCs obtained from patient B 13 days after the first detectable viral RNA (238 days after ATI). No activation to HIV-1 peptides was detected in PBMCs collected from patient A 5 days after viral rebound (89 days after ATI), but low-level activation to gag and nef peptides and higher-level activation to HLA-A02–restricted epitopes in p24 and p17 were detected in PBMCs collected 108 days after viral rebound (193 days after ATI).

Figure 2 shows HIV-1 antibody levels by the less sensitive Vitros assay and avidity over time. Antibody avidity decreased in both patients during virologic suppression after HSCT. Antibody levels and avidity increased after viral rebound in patient A, in whom virologic control was not

immediately reestablished. Despite declining avidity after rebound in patient B, who promptly resumed ART, antibody levels increased 13 days after the first detectable VL measurement.

#### DISCUSSION

Substantial reductions in HIV-1 reservoirs were seen in 2 patients who had allogeneic HSCT with HIV-1–susceptible donor cells while receiving continuous ART. Despite readily detectable proviral DNA before HSCT (15), HIV-1 RNA, proviral HIV-1 DNA, and viral outgrowth were undetectable years after HSCT using highly sensitive assays applied to plasma, PBMCs, and gut-associated lymphoid tissue. Nevertheless, HIV-1 rebound was first detected 12 and 32 weeks after ART interruption. Rebound of viremia occurred within 2 weeks after the last negative plasma HIV-1 RNA result, and both patients developed symptoms consistent with the acute retroviral syndrome. Based on previously reported proviral DNA levels before or immediately after HSCT in both patients (96 to 144 copies/ $10^6$  PBMCs) and the detection limits of sensitive quantitative assays used in this study, our findings suggest a minimum 3- $\log_{10}$  reduction in the number of circulating cells harboring proviral HIV-1 DNA after HSCT. Although allogeneic HSCT may lead to significant, sustained reductions in the HIV-1 reservoir, infected tissue or cell-bound virus persists. Persistence of these small numbers of residual infected cells seems to be sufficient to rekindle HIV-1 replication.

Our patients differed from the Berlin patient, who achieved sustained HIV-1 remission after 2 myeloablative HSCTs with resistant donor cells incapable of supporting HIV-1 replication in the event of reactivation of residual

latent reservoirs (12–14). However, phylogenetic analyses indicated that only one or a few cells or latent proviruses contributed to viral rebound after ATI in our patients. The role of specific conditioning regimens and the use of various anti-inflammatory medications after HSCT and HIV-1 persistence are largely unknown and warrant further study.

HIV-1 typically rebounds 1 to 8 weeks after ART discontinuation (6–11). One person who had undetectable HIV-1 DNA in blood or tissue but very low levels of detectable infectious virus from virus outgrowth assays had viral rebound 7 weeks after ATI (22). Posttreatment control of viral replication has been seen in patients initiating ART during acute HIV-1 infection, and several of these persons had delayed rebound after stopping ART (30, 31). However, the virus has been detected intermittently in patients who were treated early with subsequent control of the virus after ART discontinuation, and durable control was achieved in relatively few persons (30, 31). Despite frequent sampling, neither of our patients had detectable HIV-1 in PBMCs or plasma for several months after ART discontinuation before viral rebound. In addition, ultrasensitive microchimerism testing showed that nearly all PBMCs were of donor origin years after HSCT.

A chronic, ongoing graft-versus-host reaction may have been responsible for the continued surveillance and clearance of residual recipient hematopoietic cells that survived conditioning chemotherapy for our patients and the Berlin patient, some of which happened to harbor latent HIV-1. Graft-versus-tumor and more generalized graft-versus-hematopoietic effects may exist without the development or persistence of clinical graft-versus-host disease and are mediated by innate immunity and natural killer cells in addition to T-lymphocyte activity (32, 33). Furthermore, the lack of detectable HIV-1 DNA and replication-competent virus before ATI supports the hypothesis that donor cells in various tissues (such as blood and gut) were largely protected from infection by ART.

Reductions in the HIV-1 reservoir have been described in patients having myeloablative allogeneic HSCT in the setting of zidovudine monotherapy or suppressive ART (34–38). Detailed data on ART interruption after allogeneic HSCT are limited to the report of a person who had a reduction in HIV-1 DNA shortly after myeloablative HSCT and full donor chimerism (34). That patient developed grade III graft-versus-host disease of the skin and gastrointestinal tract and had rapid viral rebound within 16 days of stopping ART 4 months after transplantation (34). In contrast, our patients had been receiving ART for 2 or more years after HSCT (15) and achieved months of ART-free viral remission. Chronic graft-versus-host effects without clinically significant disease may have led to more profound reductions in viral reservoirs and ultimately delayed return of the virus. The longer interval between HSCT and ATI may also have contributed to a longer period of HIV-1 remission in our patients.

Long-lived tissue reservoirs, including host macrophages that are replaced more slowly than T-lymphocytes after HSCT (12), may have contributed to viral rebound. The recipient's residual pretransplant lymphoid tissue may have persisted despite a very high degree of donor blood chimerism, or donor cells that were inaccessible to peripheral blood and tissue sampling had become infected. For example, only a limited number of CD4<sup>+</sup> T cells were able to be surveyed from gut tissue, and more intensive sampling may have led to the detection of HIV-1. Low levels of detectable HIV-1 RNA were identified in CSF after viral rebound but were orders of magnitude lower than peripheral blood VLs. We could not obtain CSF during ATI before rebound, and further studies of tissue localization and cellular composition of this reservoir are needed.

Patients who have allogeneic HSCT experience variable HIV-specific cellular immune responses after transplantation (38). Little to no T-cell response to HIV-1 peptides was seen in our patients after HSCT or during ATI until at least 13 days after viral rebound. Thus, it seems that virus-specific adaptive immunity had a small role in controlling HIV-1 replication before rebound. The extent to which nonspecific innate immunity and graft-versus-host effects influenced the duration of ART-free remission before viral rebound is not well-defined and warrants further investigation. Both patients also had a decrease in and subsequent low-level persistence of HIV-1-specific antibodies and avidity after allogeneic HSCT. Antibody levels increased shortly after viral rebound in both patients, but avidity continued to decrease in samples from patient B, who promptly reinitiated ART. Although the Berlin patient had an even further decrease in antibody levels and avidity after HSCT, his antibodies persisted after transplantation for more than 5 years (14). The sources of residual antibodies in the HSCT patients are unknown and warrant further study.

As a result of allogeneic HSCT from donors who were not exposed to HIV, the reconstituted immune systems of our patients were HIV-naïve, as reflected by the absence of detectable virus-specific cellular immune responses. When HIV-1 rebound occurred, it mimicked the kinetics seen during acute HIV-1 infection (39). Given the rapid virologic rebound, the development of accompanying symptoms, and the emergence of a new nonnucleoside reverse transcriptase inhibitor resistance mutation despite closely monitored ART reinitiation, any future studies of ATI in the setting of allogeneic HSCT should proceed with the utmost caution. Given the limited sensitivity of currently available assays for detecting viral persistence, however, analytic treatment interruption remains the only reliable means of assessing the extent of HIV-1 reservoir depletion after therapeutic interventions.

In summary, our results suggest that allogeneic HSCT with CCR5 wild-type donor cells may lead to loss of detectable HIV-1 from blood and rectal mucosa, but viral rebound may nevertheless occur after ART interruption



despite a significant reduction in reservoir size. The definition of the nature and half-life of residual viral reservoirs is essential to achieve durable, ART-free HIV-1 remission.

From Brigham and Women's Hospital, Harvard Medical School, and Dana-Farber Cancer Institute, Boston, Massachusetts; Heinrich-Pette-Institut, Leibniz-Institut für Experimentelle Virologie, Hamburg, Germany; Blood Systems Research Institute and University of California, San Francisco, San Francisco, California; and Ragon Institute of Massachusetts General Hospital, Massachusetts Institute of Technology, and Harvard University, Cambridge, Massachusetts.

This paper was published to coincide with the 20th International AIDS Conference held in Melbourne, Australia, 20–25 July 2014.

**Note:** Dr. Henrich had full access to all of the data in the study and takes responsibility for the integrity of the data and accuracy of the data analysis.

**Disclaimer:** The findings and conclusions in this article are those of the authors and do not necessarily reflect positions or policies of the Bill & Melinda Gates Foundation or the National Institutes of Health.

**Acknowledgment:** The authors thank Athe Tsibris and Steven Deeks for helpful discussions, Mila Lebedeva for performing the antibody quantitation, Li Wen for performing the microchimerism testing, Ann LaCasse for helping with the initial study design, and Christine Palmer for helping with the flow cytometry and immune assays.

**Grant Support:** By the Foundation for AIDS Research (amfAR Research Consortium on HIV Eradication grant); National Institute of Allergy and Infectious Disease, National Institutes of Health (1K23AI098480-01A1); AIDS Clinical Trials Group Virology Support Laboratory (UM1 AI068636); Harvard University Center for AIDS Research Therapeutics Program (P30 AI060354); Delaney AIDS Research Enterprise Collaborative (U19 AI096109); and Ragon Institute of Massachusetts General Hospital, Massachusetts Institute of Technology, and Harvard University. This article is also based on research funded in part by the Bill & Melinda Gates Foundation (Global Health grant OPP1017716).

**Disclosures:** Disclosures can be viewed at [www.acponline.org/authors/icmje/ConflictOfInterestForms.do?msNum=M14-1027](http://www.acponline.org/authors/icmje/ConflictOfInterestForms.do?msNum=M14-1027).

**Reproducible Research Statement:** *Study protocol, statistical code, and data set:* Available from Dr. Henrich (e-mail, [thenrich@partners.org](mailto:thenrich@partners.org)).

**Requests for Single Reprints:** Timothy J. Henrich, MD, Division of Infectious Diseases, Brigham and Women's Hospital, Harvard Medical School, 65 Landsdowne Street, Cambridge, MA 02139; e-mail, [thenrich@partners.org](mailto:thenrich@partners.org).

Current author addresses and author contributions are available at [www.annals.org](http://www.annals.org).

## References

- Siliciano RF. What do we need to do to cure HIV infection. *Top HIV Med.* 2010;18:104-8. [PMID: 20921575]
- Richman DD, Margolis DM, Delaney M, Greene WC, Hazuda D, Pomerantz RJ. The challenge of finding a cure for HIV infection. *Science.* 2009;323:1304-7. [PMID: 19265012] doi:10.1126/science.1165706
- Dinosa JB, Kim SY, Wiegand AM, Palmer SE, Gange SJ, Cranmer L, et al. Treatment intensification does not reduce residual HIV-1 viremia in patients on highly active antiretroviral therapy. *Proc Natl Acad Sci U S A.* 2009;106:9403-8. [PMID: 19470482] doi:10.1073/pnas.0903107106

- Gandhi RT, Bosch RJ, Aga E, Albrecht M, Demeter LM, Dykes C, et al; AIDS Clinical Trials Group A5173 Team. No evidence for decay of the latent reservoir in HIV-1-infected patients receiving intensive enfuvirtide-containing antiretroviral therapy. *J Infect Dis.* 2010;201:293-6. [PMID: 20001856] doi:10.1086/649569
- Gandhi RT, Zheng L, Bosch RJ, Chan ES, Margolis DM, Read S, et al; AIDS Clinical Trials Group A5244 team. The effect of raltegravir intensification on low-level residual viremia in HIV-infected patients on antiretroviral therapy: a randomized controlled trial. *PLoS Med.* 2010;7. [PMID: 20711481] doi:10.1371/journal.pmed.1000321
- El-Sadr WM, Lundgren J, Neaton JD, Gordin F, Abrams D, Arduino RC, et al; Strategies for Management of Antiretroviral Therapy (SMART) Study Group. CD4<sup>+</sup> count-guided interruption of antiretroviral treatment. *N Engl J Med.* 2006;355:2283-96. [PMID: 17135583]
- Fischer M, Hafner R, Schneider C, Trkola A, Joos B, Joller H, et al; Swiss HIV Cohort Study. HIV RNA in plasma rebounds within days during structured treatment interruptions. *AIDS.* 2003;17:195-9. [PMID: 12545079]
- Taylor S, Boffito M, Khoo S, Smit E, Back D. Stopping antiretroviral therapy. *AIDS.* 2007;21:1673-82. [PMID: 17690564]
- Harrigan PR, Whaley M, Montaner JS. Rate of HIV-1 RNA rebound upon stopping antiretroviral therapy. *AIDS.* 1999;13:F59-62. [PMID: 10371167]
- Ruiz L, Martinez-Picado J, Romeu J, Paredes R, Zayat MK, Marfil S, et al. Structured treatment interruption in chronically HIV-1 infected patients after long-term viral suppression. *AIDS.* 2000;14:397-403. [PMID: 10770542]
- Frost SD, Martinez-Picado J, Ruiz L, Clotet B, Brown AJ. Viral dynamics during structured treatment interruptions of chronic human immunodeficiency virus type 1 infection. *J Virol.* 2002;76:968-79. [PMID: 11773372]
- Allers K, Hütter G, Hofmann J, Lodenkemper C, Rieger K, Thiel E, et al. Evidence for the cure of HIV infection by CCR5Δ32/Δ32 stem cell transplantation. *Blood.* 2011;117:2791-9. [PMID: 21148083] doi:10.1182/blood-2010-09-309591
- Hütter G, Nowak D, Mossner M, Ganepola S, Müssig A, Allers K, et al. Long-term control of HIV by CCR5 Delta32/Delta32 stem-cell transplantation. *N Engl J Med.* 2009;360:692-8. [PMID: 19213682] doi:10.1056/NEJMoa0802905
- Yukl SA, Boritz E, Busch M, Bentsen C, Chun TW, Douek D, et al. Challenges in detecting HIV persistence during potentially curative interventions: a study of the Berlin patient. *PLoS Pathog.* 2013;9:e1003347. [PMID: 23671416] doi:10.1371/journal.ppat.1003347
- Henrich TJ, Hu Z, Li JZ, Sciaranghella G, Busch MP, Keating SM, et al. Long-term reduction in peripheral blood HIV type 1 reservoirs following reduced-intensity conditioning allogeneic stem cell transplantation. *J Infect Dis.* 2013;207:1694-702. [PMID: 23460751] doi:10.1093/infdis/jit086
- Yukl SA, Shergill AK, Ho T, Killian M, Girling V, Epling L, et al. The distribution of HIV DNA and RNA in cell subsets differs in gut and blood of HIV-positive patients on ART: implications for viral persistence. *J Infect Dis.* 2013;208:1212-20. [PMID: 23852128] doi:10.1093/infdis/jit308
- Yukl SA, Gianella S, Sinclair E, Epling L, Li Q, Duan L, et al. Differences in HIV burden and immune activation within the gut of HIV-positive patients receiving suppressive antiretroviral therapy. *J Infect Dis.* 2010;202:1553-61. [PMID: 20939732] doi:10.1086/656722
- Malnati MS, Scarlatti G, Gatto F, Salvatori F, Cassina G, Rutigliano T, et al. A universal real-time PCR assay for the quantification of group-M HIV-1 proviral load. *Nat Protoc.* 2008;3:1240-8. [PMID: 18600229] doi:10.1038/nprot.2008.108
- Henrich TJ, Gallien S, Li JZ, Pereyra F, Kuritzkes DR. Low-level detection and quantitation of cellular HIV-1 DNA and 2-LTR circles using droplet digital PCR. *J Virol Methods.* 2012;186:68-72. [PMID: 22974526] doi:10.1016/j.jviromet.2012.08.019
- Palmer S, Wiegand AP, Maldarelli F, Bazmi H, Mican JM, Polis M, et al. New real-time reverse transcriptase-initiated PCR assay with single-copy sensitivity for human immunodeficiency virus type 1 RNA in plasma. *J Clin Microbiol.* 2003;41:4531-6. [PMID: 14532178]
- Chun TW, Carruth L, Finzi D, Shen X, DiGiuseppe JA, Taylor H, et al. Quantification of latent tissue reservoirs and total body viral load in HIV-1 infection. *Nature.* 1997;387:183-8. [PMID: 9144289]
- Chun TW, Justement JS, Murray D, Hallahan CW, Maenza J, Collier AC, et al. Rebound of plasma viremia following cessation of antiretroviral therapy despite profoundly low levels of HIV reservoir: implications for eradica-



- tion. *AIDS*. 2010;24:2803-8. [PMID: 20962613] doi:10.1097/QAD.0b013e328340a239
23. Siliciano JD, Siliciano RF. Enhanced culture assay for detection and quantitation of latently infected, resting CD4<sup>+</sup> T-cells carrying replication-competent virus in HIV-1-infected individuals. *Methods Mol Biol*. 2005;304:3-15. [PMID: 16061962]
24. Keele BF, Giorgi EE, Salazar-Gonzalez JF, Decker JM, Pham KT, Salazar MG, et al. Identification and characterization of transmitted and early founder virus envelopes in primary HIV-1 infection. *Proc Natl Acad Sci U S A*. 2008;105:7552-7. [PMID: 18490657] doi:10.1073/pnas.0802203105
25. Duong YT, Qiu M, De AK, Jackson K, Dobbs T, Kim AA, et al. Detection of recent HIV-1 infection using a new limiting-antigen avidity assay: potential for HIV-1 incidence estimates and avidity maturation studies. *PLoS One*. 2012;7:e33328. [PMID: 22479384] doi:10.1371/journal.pone.0033328
26. Altfeld MA, Trocha A, Eldridge RL, Rosenberg ES, Phillips MN, Addo MM, et al. Identification of dominant optimal HLA-B60- and HLA-B61-restricted cytotoxic T-lymphocyte (CTL) epitopes: rapid characterization of CTL responses by enzyme-linked immunospot assay. *J Virol*. 2000;74:8541-9. [PMID: 10954555]
27. Lee TH, Chafets DM, Reed W, Wen L, Yang Y, Chen J, et al. Enhanced ascertainment of microchimerism with real-time quantitative polymerase chain reaction amplification of insertion-deletion polymorphisms. *Transfusion*. 2006;46:1870-8. [PMID: 17076840]
28. Lee TH, Paglieroni T, Utter GH, Chafets D, Gosselin RC, Reed W, et al. High-level long-term white blood cell microchimerism after transfusion of leukoreduced blood components to patients resuscitated after severe traumatic injury. *Transfusion*. 2005;45:1280-90. [PMID: 16078913]
29. Li JZ, Gallien S, Do TD, Martin JN, Deeks S, Kuritzkes DR, et al. Prevalence and significance of HIV-1 drug resistance mutations among patients on antiretroviral therapy with detectable low-level viremia. *Antimicrob Agents Chemother*. 2012;56:5998-6000. [PMID: 22890763] doi:10.1128/AAC.01217-12
30. Sáez-Cirión A, Bacchus C, Hocqueloux L, Avettand-Fenoel V, Girault I, Lecuroux C, et al; ANRS VISCONTI Study Group. Post-treatment HIV-1 controllers with a long-term virological remission after the interruption of early initiated antiretroviral therapy ANRS VISCONTI Study. *PLoS Pathog*. 2013;9:e1003211. [PMID: 23516360] doi:10.1371/journal.ppat.1003211
31. Kaufmann DE, Lichterfeld M, Altfeld M, Addo MM, Johnston MN, Lee PK, et al. Limited durability of viral control following treated acute HIV infection. *PLoS Med*. 2004;1:e36. [PMID: 15526059]
32. van Besien K. Allogeneic transplantation for AML and MDS: GVL versus GVHD and disease recurrence. *Hematology Am Soc Hematol Educ Program*. 2013;2013:56-62. [PMID: 24319163] doi:10.1182/asheducation-2013.1.56
33. Murphy WJ, Parham P, Miller JS. NK cells—from bench to clinic. *Biol Blood Marrow Transplant*. 2012;18:S2-7. [PMID: 22226108] doi:10.1016/j.bbmt.2011.10.033
34. Avettand-Fenoel V, Mahlaoui N, Chaix ML, Milliancourt C, Burgard M, Cavazzana-Calvo M, et al. Failure of bone marrow transplantation to eradicate HIV reservoir despite efficient HAART [Letter]. *AIDS*. 2007;21:776-7. [PMID: 17413704]
35. Contu L, La Nasa G, Arras M, Pizzati A, Vacca A, Carcassi C, et al. Allogeneic bone marrow transplantation combined with multiple anti-HIV-1 treatment in a case of AIDS. *Bone Marrow Transplant*. 1993;12:669-71. [PMID: 8136753]
36. Holland HK, Saral R, Rossi JJ, Donnemberg AD, Burns WH, Beschoner WE, et al. Allogeneic bone marrow transplantation, zidovudine, and human immunodeficiency virus type 1 (HIV-1) infection. Studies in a patient with non-Hodgkin lymphoma. *Ann Intern Med*. 1989;111:973-81. [PMID: 2512828]
37. Huzicka I. Could bone marrow transplantation cure AIDS?: review. *Med Hypotheses*. 1999;52:247-57. [PMID: 10362285]
38. Woolfrey AE, Malhotra U, Harrington RD, McNevin J, Manley TJ, Riddell SR, et al. Generation of HIV-1-specific CD8<sup>+</sup> cell responses following allogeneic hematopoietic cell transplantation. *Blood*. 2008;112:3484-7. [PMID: 18698002] doi:10.1182/blood-2008-05-157511
39. Daar ES, Moudgil T, Meyer RD, Ho DD. Transient high levels of viremia in patients with primary human immunodeficiency virus type 1 infection. *N Engl J Med*. 1991;324:961-4. [PMID: 1823118]

## EASY SLIDES

Download tables and figures as PowerPoint slides at [www.annals.org](http://www.annals.org).

**Current Author Addresses:** Drs. Henrich, Li, and Kuritzkes; Ms. Hanhauser; and Ms. Heisey: Division of Infectious Diseases, Brigham and Women's Hospital, Harvard Medical School, 65 Landsdowne Street, Cambridge, MA 02139.

Dr. Marty and Ms. Robles: Brigham and Women's Hospital, 75 Francis Street, Boston, MA 02115.

Mr. Sirignano and Dr. Altfeld: Abt 8, Heinrich-Pette-Intitut, Leibniz-Institut für Experimentelle Virologie (HPI), Martinistrasse 52, 20251 Hamburg, Germany.

Drs. Keating, Lee, and Busch: Blood Systems Research Institute, 270 Masonic Avenue, San Francisco, CA 94118.

Dr. Davis: Massachusetts General Hospital, 55 Fruit Street, Boston, MA 02114.

Dr. Hill: Harvard University, One Brattle Square, Cambridge, MA 02139.

Drs. Armand and Soiffer: Dana-Farber Cancer Institute, 450 Brookline Avenue, Boston, MA 02215.

**Author Contributions:** Conception and design: T.J. Henrich, M.P. Busch, M. Altfeld, D.R. Kuritzkes.

Analysis and interpretation of the data: T.J. Henrich, E. Hanhauser, F.M. Marty, M.N. Sirignano, S. Keating, J.Z. Li, A.L. Hill, M.P. Busch, M. Altfeld, D.R. Kuritzkes.

Drafting of the article: T.J. Henrich, M.P. Busch, R.J. Soiffer, D.R. Kuritzkes.

Critical revision of the article for important intellectual content: T.J. Henrich, F.M. Marty, M.N. Sirignano, B.T. Davis, J.Z. Li, M.P. Busch, P. Armand, R.J. Soiffer, D.R. Kuritzkes.

Final approval of the article: T.J. Henrich, F.M. Marty, M.N. Sirignano, B.T. Davis, J.Z. Li, M.P. Busch, P. Armand, M. Altfeld, D.R. Kuritzkes. Provision of study materials or patients: T.J. Henrich, F.M. Marty, R.J. Soiffer.

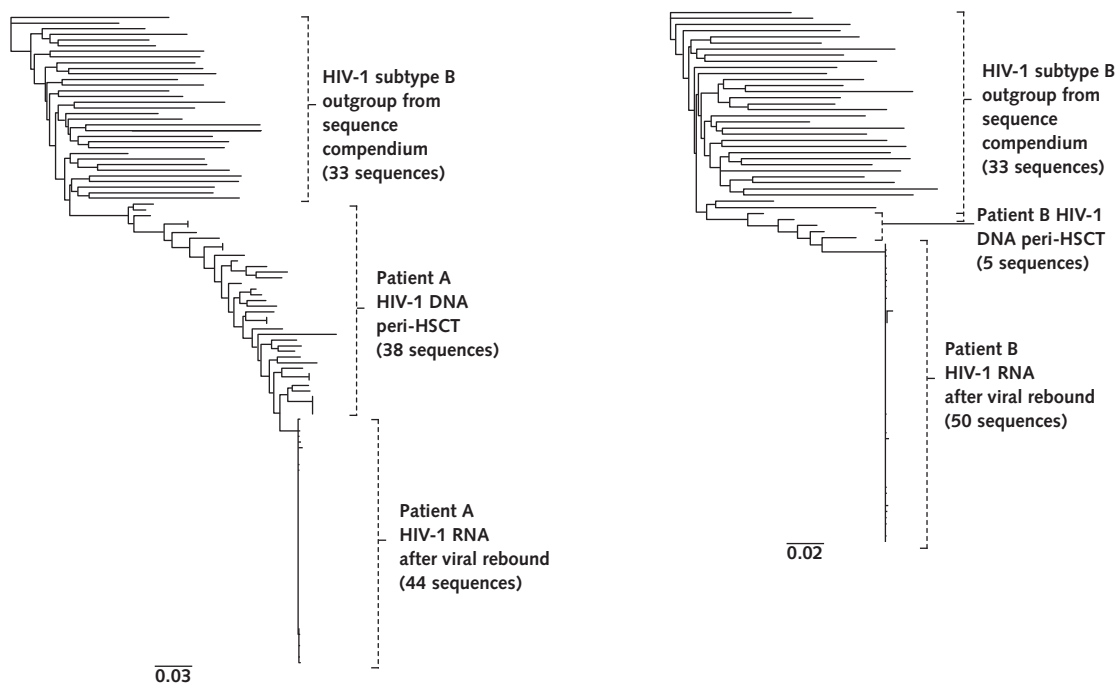
Statistical expertise: A.L. Hill, M.P. Busch.

Obtaining of funding: T.J. Henrich, D.R. Kuritzkes.

Administrative, technical, or logistic support: T.J. Henrich, E. Hanhauser, F.M. Marty, Y.P. Robles, B.T. Davis, M.P. Busch.

Collection and assembly of data: T.J. Henrich, E. Hanhauser, M.N. Sirignano, S. Keating, T.H. Lee, Y.P. Robles, B.T. Davis, J.Z. Li, A. Heisey, M.P. Busch, P. Armand, M. Altfeld.

**Appendix Figure. Phylogenetic relationships between peri-HSCT HIV-1 DNA and rebound HIV-1 plasma RNA.**



Phylogenetic trees of near–full-length, single-genome HIV-1 envelope sequences for patient A (*left*) and patient B (*right*) are shown. Compared with an outgroup of HIV-1 subtype B sequences from the Los Alamos National Laboratory HIV Sequence Database Compendium, rebound HIV-1 envelope sequences were highly related to peri-HSCT cell-associated viral DNA. Rebound HIV-1 envelope sequences were monophyletic with a very high degree of intrasample sequence homology, suggesting that viral reseeding occurred from only one or a few cells or proviruses. Maximum likelihood trees were constructed using a general time-reversible model after stripping gaps and ambiguous alignment regions. Distance scale bars denote nucleotide substitutions per site. HSCT = hematopoietic stem cell transplantation.